

Use of Intraoperative Computed Tomography in Complex Facial Fracture Reduction and Fixation

Amr Rabie, MD, Ahmed M. S. Ibrahim, MD, Bernard T. Lee, MD, and Samuel J. Lin, MD

Background: Using conventional complex facial fracture management principles, confirmation of adequate facial fracture reduction can be achieved only by obtaining a postoperative computed tomography (CT) scan. If the CT scan revealed any discrepancy in fracture alignment, additional procedures for correction may be required. The concept of intraoperative CT scanning provides immediate postreduction or intraoperative information that orients the surgeon to the potential need for additional maneuvers for improved fracture reduction and osseous fixation. We assessed the early technical feasibility of real-time intraoperative CT scanning using the xCAT ENT (Xoran Technologies, Inc, Ann Arbor, MI), for monitoring of fracture reduction with the possibility of immediate intraoperative revision if needed, potentially obviating the need for revision procedures.

Methods: Three adult patients were studied who were admitted from the emergency department. During their respective reconstructive procedures, the xCAT ENT was used to provide images: Axial, coronal, sagittal, and three-dimensional reformatted images with segmentation of the CT data set and mirroring of the reconstructed side to the unaffected side were used for precise measurement and comparison of the reconstruction. The scans were examined by the operating surgeon and an intraoperative decision was made as to whether immediate revision was required.

Results: Facial fracture management with intraoperative CT monitoring was changed in 2 of the 3 cases. One patient who underwent immediate revision had an open reduction–internal fixation after cranialization. The second patient who had a revision had a persistent subcondylar fracture that was found not amenable to closed reduction.

Conclusions: The intraoperative CT scan may positively change the outcome of facial fracture reduction especially when dealing with complex fractures. Additional studies are needed for studying its potential impact in monitoring reduction of facial fractures.

Key Words: Intraoperative CT, facial fracture, orbital floor fracture, ZMC fracture, zygomatic arch fracture

(*J Craniofac Surg* 2011;22: 1466–1467)

When using conventional complex facial fracture management principles, the confirmation of adequate facial fracture reduction can usually be achieved only by obtaining a postoperative computed tomography (CT) scan. Subsequently, if the CT scan reveals significant discrepancy in fracture alignment, additional procedures for correction may be required. The concept of intraoperative CT scanning provides immediate postreduction and intraoperative information that orient the surgeon to the potential need for additional maneuvers for improved fracture reduction and osseous fixation. Thus, intraoperative CT scanning may provide a higher degree of accuracy regarding the outcome of an operation as bony irregularities and depressions can easily be masked by soft tissue edema associated with the underlying trauma; significant soft tissue edema may limit the optimal reduction of fractures.

We assessed the early technical feasibility of real-time intraoperative CT scanning using the xCAT ENT (Xoran Technologies, Inc, Ann Arbor, MI) device, which is a compact, portable CT scanner during surgical reduction of complex facial and/or nasal fractures. In the future, subjects enrolled in a current study will potentially benefit from having real-time intraoperative CT monitoring of their fractures with the possibility of immediate intraoperative revision if needed, potentially obviating the need for revisional procedures subsequently.

PATIENTS AND METHODS

This study was approved by the Beth Israel Deaconess Medical Center institutional review board. In this preliminary series, 3 adult patients were enrolled who were admitted from the emergency department: a 43-year-old man with multiply comminuted anterior and posterior frontal sinus and frontal bone fractures, a 37-year-old woman with panfacial fractures including a mandibular fracture, and a 59-year-old woman with multiple facial

From the Division of Plastic Surgery, Department of Surgery, Beth Israel Deaconess Medical Center, Harvard Medical School, Boston, Massachusetts.

Received November 21, 2010.

Accepted for publication January 30, 2011.

Address correspondence and reprint requests to Samuel J. Lin, MD, Division of Plastic Surgery, 110 Francis St Suite 5A, Boston, MA 02215; E-mail: sjlin@bidmc.harvard.edu

Supplemental digital content is available for this article. Direct URL citations appear in the printed text and are provided in the HTML and PDF versions of this article on the journal's Web site (www.jcraniofacialsurgery.com).

The authors report no conflicts of interest.

Copyright © 2011 by Mutaz B. Habal, MD

ISSN: 1049-2275

DOI: 10.1097/SCS.0b013e31821d1982

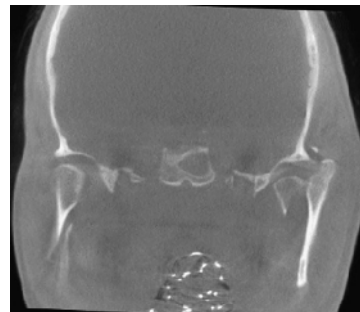


FIGURE 1. Intraoperative CT image: coronal view of patient 2 revealing the displacement of the left condylar fracture after an attempt at closed reduction.