

*Hand Surgery*. 5th ed. Philadelphia: Elsevier Churchill Livingstone; 2005:2211–2263.

- Phalen GS. Neurilemmomas of the forearm and hand. *Clin Orthop Relat Res*. 1976;114:219–222.
- Rockwell GM, Thoma A, Salama S. Schwannoma of the hand and wrist. *Plast Reconstr Surg*. 2003;111:1227–1232.

### Unusual Anterolateral Thigh Donor-Site Complications: Intraneural Hemangioma and Traumatic Neuroma

Sir:

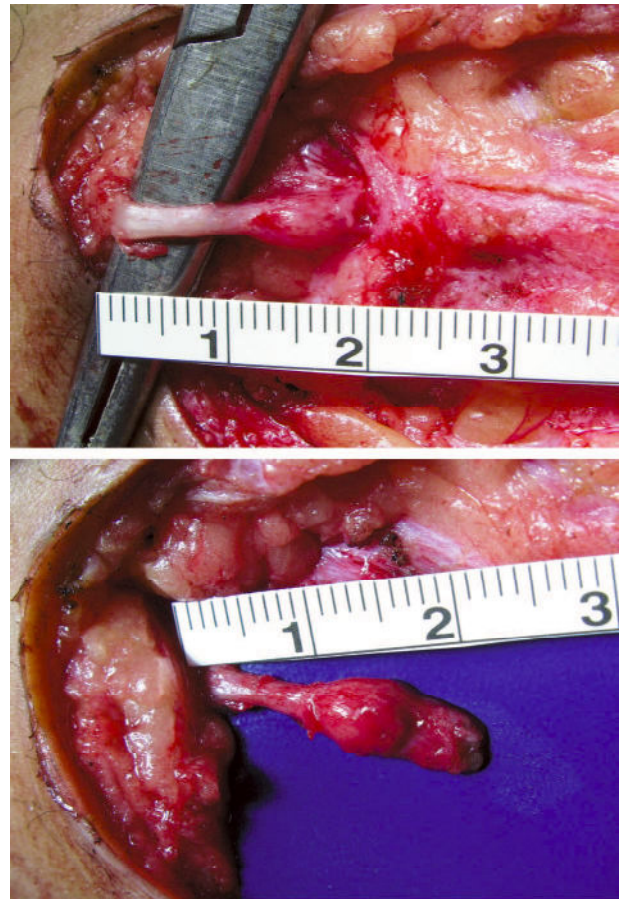
**D**onor-site morbidities following anterolateral thigh flap surgery are infrequent and usually minor. We report two cases of unusual anterolateral thigh donor-site complications: a case of traumatic neuroma and a case of intraneural hemangioma.

In the first case, a 52-year-old man presented with a multiply recurrent dermatofibrosarcoma protuberans. He underwent resection of the lesion, resulting in a 5 × 8-cm defect of the left forehead, which was reconstructed with an anterolateral thigh free flap. Four months later, the patient noticed tingling and pain along the upper portion of the incision at the anterolateral thigh flap donor site. Examination revealed severe tenderness with a positive Tinel sign. Exploration of the donor site revealed a neuroma measuring 25 × 6 × 3 mm in the scar tissue at the level of fascial closure (Fig. 1). Pathologic examination confirmed the diagnosis of neuroma with suture granuloma. The patient's symptoms resolved completely, immediately after neuroma excision.

In the second case, a 73-year-old woman with a left facial leiomyosarcoma underwent tumor ablation and anterolateral thigh flap reconstruction of the soft-tissue defect and facial nerve grafting using the lateral femoral cutaneous nerve harvested with the anterolateral thigh flap. One year later, she complained of throbbing pain and a positive Tinel sign at the inferior portion of the anterolateral thigh donor site. Exploration revealed a small nerve emanating from the vastus lateralis muscle and traversing inferolaterally into the skin. The nerve was excised and pathologic examination showed an arteriovenous type hemangioma. The patient's symptoms resolved immediately following surgery.

Although sensory deficits in the lateral femoral cutaneous nerve distribution are common,<sup>1</sup> symptoms of nerve compression at the anterolateral thigh flap donor site have not been reported. In the senior author's experience of 250 anterolateral thigh free flaps, only two patients have presented with symptoms consistent with neuroma, as reported here.

Traumatic neuromas may arise following complete or partial nerve division or repair, stretching, or crushing of the nerves as a result of the attempts of peripheral nerve axons to innervate the distal nerve segment. Microscopically, neuromas contain fibrous tissue, blood vessels, clusters of unmyelinated axons, and Schwann cells.<sup>2</sup> Intraneural arteriovenous hemangioma is rare. In the literature, few cases of peripheral intraneural



**Fig. 1.** A clinically apparent neuroma at the anterolateral thigh flap donor site.

hemangiomas have been reported, with the median nerve accounting for the majority of cases, followed by the tibial nerve. They usually present with pain and other nerve compression and nerve entrapment symptoms.<sup>3–5</sup>

Clinical symptoms and findings on physical examination may be sufficient to establish a diagnosis, and surgical exploration is indicated in symptomatic patients to relieve pain. Surgical excision of the lesion is simple and extremely effective, as evidenced in these two cases. With any neuroma, prevention involves burying the cutting end of the nerve in deep tissue at the time of surgery/flap harvesting. However, in the second patient, it appears that a new nerve had grown through the vastus lateralis muscle to the skin, forming an intraneural hemangioma. It is unclear whether such an event is preventable.

DOI: 10.1097/PRS.0b013e3181c72827

Samuel J. Lin, M.D.

Amr Rabie, M.D.

Division of Plastic Surgery  
Beth Israel Deaconess Medical Center  
Boston, Mass.